

Triamcinolone acetonide injection and Injection site atrophy

Introduction

Triamcinolone acetonide (Kenacort-A®) is a synthetic glucocorticosteroid with marked anti-inflammatory action. It has been approved for the Dutch market since September 1966. The intra-articular or intrabursal administration of triamcinolone acetonide injectable suspension is indicated as adjunctive therapy for short-term administration in *acute gouty arthritis, acute and subacute bursitis, acute nonspecific tenosynovitis, epicondylitis, rheumatoid arthritis, synovitis, or osteoarthritis*.

The intralesional administration of triamcinolone acetonide injectable suspension is indicated for *alopecia areata; discoid lupus erythematosus; keloids; localized hypertrophic, infiltrated, inflammatory lesions of granuloma annulare, lichen planus, lichen simplex chronicus (neurodermatitis), and psoriatic plaques; necrobiosis lipoidica diabetorum*. Triamcinolone acetonide injection may also be useful in cystic tumors of an aponeurosis or tendon (ganglia) (1).

Occurrence of local atrophy after corticosteroid injection is described in the literature. It is more common with preparations with a lesser degree of water solubility. Although the condition is often reversible, instances of long-term disfigurement are well documented (2;3).

Reports

Between 28-09-1993 and 20-02-2017, the database of the Netherlands Pharmacovigilance Centre Lareb contained 13 reports of subcutaneous injection site atrophy associated with the use of triamcinolone acetonide injection. The reactions were coded with multiple MedDRA® terms. The reports are listed in Table 1.

Table 1. Cases of injection site atrophy associated with the use of triamcinolone acetonide injection in the database of the Netherlands Pharmacovigilance Centre

Number, Gender, Age, Reporter	Suspect Drug	Concomitant	Reaction	Latency, Action taken, Outcome
A: 7896, F, 31-40 Unknown, Physician	Triamcinolone acetonide injection 40MG/ML, Indication unknown	Dapsone	Injection site atrophy (subcutaneous, upper legs)	1 year (not clear after how many injections, most likely multiple injections given) Drug withdrawn, Outcome unknown
B: 17839, F, 31-40, Physician	Triamcinolone acetonide injection 40MG/ML, Indication unknown	Folic acid	Injection site atrophy, left upperarm	3 Months Drug withdrawn, Outcome unknown
C: 27951, F, 31-40, Physician	Triamcinolone acetonide injection 40MG/ML, Indication: Allergy NOS	Mizolastine Levocabastine Iron sorbitol citrate Diclofenac	Injection site atrophy (subcutaneous right buttock)	Latency unknown, Injection given once, Outcome unknown
D: 29009, F, 31-40, General Practitioner	Triamcinolone acetonide injection 40MG/ML (3cc) Lidocainehydrochloride 1ml= 10mg Fna Ampl (7cc), Indication: Bursitis	Doxycycline	Injection site atrophy (lipodystrophy), after a progressive indurated swelling	Drug withdrawn, reaction progressive since day injection was given first pain, progressive indurated swelling, lipodystrophy
E: 184263, F, 61-70 General Practitioner	Triamcinolone acetonide injection 40MG/ML, Indication: Tenosynovitis		Injection site atrophy Skin discolouration (purple)	5 Weeks Injection given once Injection site atrophy not recovered at time of reporting (6 months after occurrence)
F: 198876, F, 21-30 Consumer	Triamcinolone acetonide injection 40MG/ML, Indication:		Injection site atrophy (lipoatrophy,	3 Days Injection given once, Not recovered at time of reporting

	Bursitis		several cm)	(2 months after occurrence)
G: 233627, F, 11-20 Physician	Triamcinolone acetone injection 40MG/ML Indication: Asthma (evaluation steroid resistance)	Formoterol with beclomethason, Mometasone Furoate (nasal spray), Levocetirizine	Injection site atrophy (subcutaneous) Skin hypopigmentation	1 Day drug given once intramuscular, 5 months later the patient has not recovered
H: 241757, F, 21-30 Physician via MAH (Literature case)	Triamcinolone acetone injection 40MG/ML Lidocaine Injvl 1mg/ML Indication: Neuroma		Fat atrophy (foot) Skin depigmentation Skin thinning of Injection site	Latency within one month, injection given once, one year later re-pigmentation however thinning of the skin had fat atrophy had not recovered.
I: 234767, F, 21-30	Triamcinolone acetone injection 40MG/ML, Indication: Hay fever		Injection site hematoma followed by Injection site atrophy (4cm x1 cm on upper arm)	drug given once intramuscular, 7 months later the patient has not recovered, underwent plastic surgery twice
J: 144325 F, 21-30, Physician via MAH	Triamcinolone acetone injection 40MG/ML, Indication: bursitis		Fat atrophy	Two consecutive injections on 11- 10-20-11 and 28-11-2011, in January 2012 diagnosed with subcutaneous fat atrophy.
K: 155648 F, 21-30 Consumer	Triamcinolone acetone injection 40MG/ML, Indication: tendonitis		Fat atrophy hand	1 week, Not recovered 6 months later, Patient referred to plastic surgeon for treatment
L: 225437 F, 51-60 Physician	Triamcinolone acetone injection 40MG/ML, Indication: Rheumatoid arthritis		Skin atrophy, Fat necrosis buttock	Exact latency unknown, 2 intramuscular with triamcinolone (Kenacort) in December 2015. Reaction occurred on 14-12-2015. Patient has recovered with sequel.
M: 231578 F, 21-30 Specialist doctor	Triamcinolone acetone injection 40MG/ML, Indication: Rheumatoid arthritis		Fat atrophy Skin hypopigmentation (right upper quadrant buttock)	1 day, drug given once intramuscular, 10 months later the patient has not recovered

More information on the cases is given below

- C: Initially Iron sorbitol citrate injection was seen as a suspect drug by the reporter. This was given 5 times in alternating the left and right buttock. However, triamcinolone acetone injection was later deemed the most likely suspect drug by the reporter.
- F: Patient received an earlier injection with triamcinolone acetone on an injection site with less adipose tissue, this earlier injection did not lead to lipodatrophy).
- H: Literature case (4). An injection of 40 mg triamcinolone acetone mixed with 2 ml 1% lidocaine was administered in the interdigital space between the 3rd and the 4th metatarsal head. The needle was inserted using a dorsal approach, perpendicular to the skin. Symptoms improved over several weeks but at 1-month follow-up, patient reported local skin depigmentation. On clinical examination thinning of the skin with atrophy of fat at the injection site were found. Although there was no complete resolution of the pain, patient was satisfied with the clinical results and no further treatment was considered. At 3 months follow-up however, the cutaneous changes had worsened, showing further local depigmentation and thinning of the skin in combination with pale streaks of depigmentation following a pattern of lymph vessels along the ankle and further half way up to the knee. Patient was referred to a dermatologist and the clinical diagnosis of steroid induced depigmentation along lymph vessels was confirmed clinically. One year after the injection there was no pain and re-pigmentation had commenced over the hypo-pigmented streaks. The thinning of the skin and fat atrophy at the injection site however showed no improvement.
- I: Follow-up: The patient underwent surgery twice because the injection site atrophy was so large this was her only treatment option. After the first surgery, the wound became severely inflamed and the patient needed professional wound care at the hospital and at home. After a month the wound was so inflamed that a second operation was necessary. This operation was successful, although the patient is left with a large scar.



Case 1, picture used with permission of the patient

Other sources of information

SmPC

The Dutch SmPC (1) of triamcinolone acetonide warns in section 4.4. that in intra-articular or intrabursal administration and with injection of triamcinolone acetonide in the tendon sheath excessive swelling of the articular capsule and deposition of the steroid along the needle trace should be avoided in intra-articular injection, as this may lead to subcutaneous atrophy.

Section 4.8 of the SmPC mentions skin atrophy and muscle atrophy. It also mentions that after intradermal administration subcutaneous and cutaneous atrophy have sometimes occurred.

The patient information leaflet (PIL) describes as adverse drug reactions 'cutaneous atrophy' (*perkamentachtige, haarloze, gemakkelijk rimpelbare dunne huid (huidatrofie)*). For patients it might not be clear from this text that subcutaneous atrophy on the injection site might occur, which may take a prolonged period to recover or might even require a cosmetic procedure.

Literature

Subcutaneous atrophy is well described in the literature as an adverse reaction of corticosteroid injections, including triamcinolone (2-7).

To illustrate, two similar cases to those reported to Lareb are described in more detail below. A 42 year old female received intramuscular injection of 40 mg triamcinolone acetonide on the right upper arm for the treatment of pollen allergy. Subcutaneous atrophy appeared at the injection site a few days after. Thinning of the skin in the area of 4 x 1.5 cm and subcutaneous atrophy were detected in the right upper arm. *See the figure below.* According to the authors subcutaneous atrophy after local injection of corticosteroids is generally considered to be reversible and usually it improves within about 1 year after the injection. However, in this patient one year since local injection, subcutaneous atrophy did not improve and a fat injection using autologous fat was performed with a good cosmetic result (3).

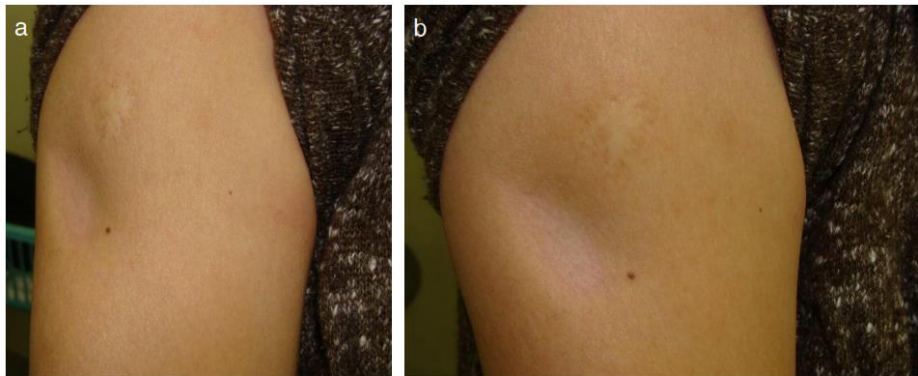
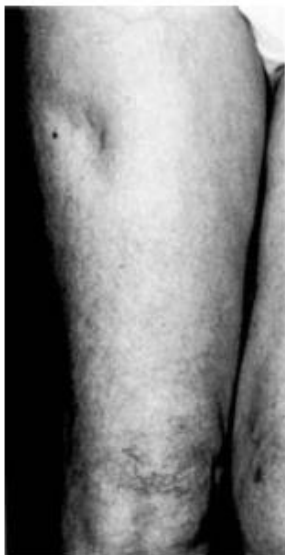

Fig. 1a, b Findings at the initial examination. Thinning of the skin in the area of 4 × 1.5 cm and subcutaneous atrophy in the right upper arm.



A 41-50 year-old woman with rheumatoid arthritis was given triamcinolone acetonide (120 mg; 40 mg/ml), injected intramuscularly into her right upper thigh by her general practitioner, for a flare of her disease. This injection was helpful in suppressing the active disease, but left her with an indentation at the site of the injection, secondary to subcutaneous tissue atrophy (8). From the case description is it unclear if the reaction was reversible.

Figure from Ching et al.(8)

Databases

There are 645 cases of Injection site atrophy in the WHO database, including the MedDRA LLTs Atrophy injection site n= 10, Injection site atrophy n= 624, Injection site fat atrophy n= 4, Lipoatrophy injection site n=8. We did not calculate disproportionality in the Lareb, nor the WHO database (9) because it was currently not possible to restrict the calculation of the ROR to injections only and an unadjusted ROR gives rise to extremely high RORs with very wide confidence intervals for triamcinolone injections.

Prescription data (10)

Drug	2012	2013	2014	2015	2016
Triamcinolone acetonide	182,750	189,280	197,070	197,210	205,940

Mechanism

When corticosteroids are injected locally there is an inhibitory action on proliferation of fibroblast in a dose-related manner and that decomposition of collagen is accelerated by the hyperfunctioning of collagenase activation. Clinically, the symptom of disappearance of local subcutaneous fat tissue without inflammatory findings and pathohistologically, the symptom showing micronization of fat tissue are generally called localized involutinal lipoatrophy (3). According to the report by Dahl et al.(11) in 1996, local injection of corticosteroids or antibiotics was found to be present in 62% of the localized involutinal lipoatrophy.

Outcomes described in the literature for subcutaneous injection site atrophy vary. For instance Friedman et al.(12) describe cases with a natural recovery within one year. However, there are some cases reporting no signs of improvement after a prolonged period of time, where a surgical treatment is necessary (3).

Discussion and conclusion

Subcutaneous fat atrophy may occur by injection of any type of steroid into the soft tissue. However, if steroids with suitable solubility and potency are used, the risk of subcutaneous fat atrophy and hypopigmentation can be reduced. Therefore, steroids with low solubility, such as triamcinolone acetonide, are preferably injected into the joint of deep structures such as the knee, elbow, and shoulder, whereas steroids with high solubility, such as betamethasone sodium and dexamethasone, are preferably injected into soft tissues such as the bursa, tendon sheath, metacarpophalangeal joint, proximal phalangeal joint, and carpal tunnel. Steroids cause fewer complications if their efficacy duration is shorter. In addition, for the prevention of subcutaneous fat atrophy, compressing the injection site with gauze is recommended in the literature after pulling out the needle to prevent steroid leakage along the needle track (6;13). However, this is not mentioned in The SmPC. Subcutaneous fat atrophy has been known to last for 6-12 months after corticosteroid injection, and has shown to be reversible and resolved within one year in some published cases. If subcutaneous fat atrophy lasts for more than one year, surgical treatments such as fat graft and fat injection can be considered (3;13). In the 13 cases reported to Lareb, in 7 cases the patient had not recovered 2-12 months after reporting. Two patients required surgery. One patient has recovered with sequel and the outcome was unknown in other cases.

None of the cases reported to Lareb explicitly mention excessive swelling of the joint capsule and deposition of the steroid along the needle trace which the SmPC warns about. However, we cannot be sure that injection technique has not played a role in the occurrence of the ADR. Interestingly, all patients in the cases reported to Lareb are female. Cases in the literature also predominately describe women. Friedman et al. already speculated in 1988 if women could be more at risk for this ADR (12). However, an exact mechanism behind the difference in sex distribution for this ADR was not found.

To conclude; Although subcutaneous atrophy at the injection site after triamcinolone injection is described in the literature and the SmPC, for patients it will not be clear from the PIL that this ADR may occur. Also, both SmPC and PIL do not warn for the possible irreversibility (and hence cosmetic effects) of this ADR. Attention for this ADR is warranted.

Reference List

- (1) Medicines Evaluation Board (MEB). Kenacort-A 10, suspensie voor injectie 10 mg/ml. <https://db.cbg-meb.nl/IB-teksten/h01591.pdf> 2017 March 3 [cited 2017 Nov 9]; Available from: URL: www.cbg-meb.nl
- (2) Jacobs MB. Local subcutaneous atrophy after corticosteroid injection. *Postgrad Med* 1986 Sep 15;80(4):159-60.
- (3) Imagawa K, Ohkuma S. A case of fat injection for treating subcutaneous atrophy caused by local administration of corticosteroid. *Tokai J Exp Clin Med* 2010 Jul 20;35(2):66-9.
- (4) van Vendeloo SN, Ettema HB. Skin depigmentation along lymph vessels of the lower leg following local corticosteroid injection for interdigital neuroma. *Foot Ankle Surg* 2016 Jun;22(2):139-41.
- (5) Steffey JM. Letter: Subcutaneous atrophy following intramuscular administration of triamcinolone acetonide. *Am J Dis Child* 1973 Oct;126(4):561-2.
- (6) Park SK, Choi YS, Kim HJ. Hypopigmentation and subcutaneous fat, muscle atrophy after local corticosteroid injection. *Korean J Anesthesiol* 2013 Dec;65(6 Suppl):S59-S61.
- (7) Dahl PR, Zalla MJ, Winkelmann RK. Localized involutinal lipoatrophy: a clinicopathologic study of 16 patients. *J Am Acad Dermatol* 1996 Oct;35(4):523-8.
- (8) Ching DW, Dellow PM. Clinical images: steroid-induced subcutaneous tissue atrophy. *Arthritis Rheum* 1997 Feb;40(2):294.
- (9) Uppsala Monitoring Centre. WHO Global Individual Case Safety Reports database (Vigibase). <https://tools-umc.org/webroot/> (access restricted) 2015 [cited 2015 Nov 5];
- (10) College for Health Insurances. GIP database. <http://www.gipdatabank.nl/index.asp?scherms=tabellenFrameSet&infoType=g&tabel=01-basis&item=J01FF> 2014 [cited 2015 Oct 30];
- (11) Dahl PR, Zalla MJ, Winkelmann RK. Localized involutinal lipoatrophy: a clinicopathologic study of 16 patients. *J Am Acad Dermatol* 1996 Oct;35(4):523-8.
- (12) Friedman SJ, Butler DF, Pittelkow MR. Perilesional linear atrophy and hypopigmentation after intralesional corticosteroid therapy. Report of two cases and review of the literature. *J Am Acad Dermatol* 1988 Sep;19(3):537-41.
- (13) Papadopoulos PJ, Edison JD. The Clinical Picture - Soft tissue atrophy after corticosteroid injection. *Cleve Clin J Med* 2009 Jun;76(6):373-4.

This signal has been raised on February 1, 2018. It is possible that in the meantime other information became available. For the latest information, including the official SmPC's, please refer to website of the MEB www.cbg-meb.nl